MALIGNANT BONE TUMORS

OSTEOSARCOMA

- The **maxilla** and **mandible** are equally affected. **Mandibular** tumors arise in the **posterior body and ramus**.
- **Maxillary** lesions are commonly in the **inferior portion**.
- **Swelling** and **pain** are the most common symptoms. Other features: **loosening of the teeth**, **parasthesia**, and **nasal obstruction**

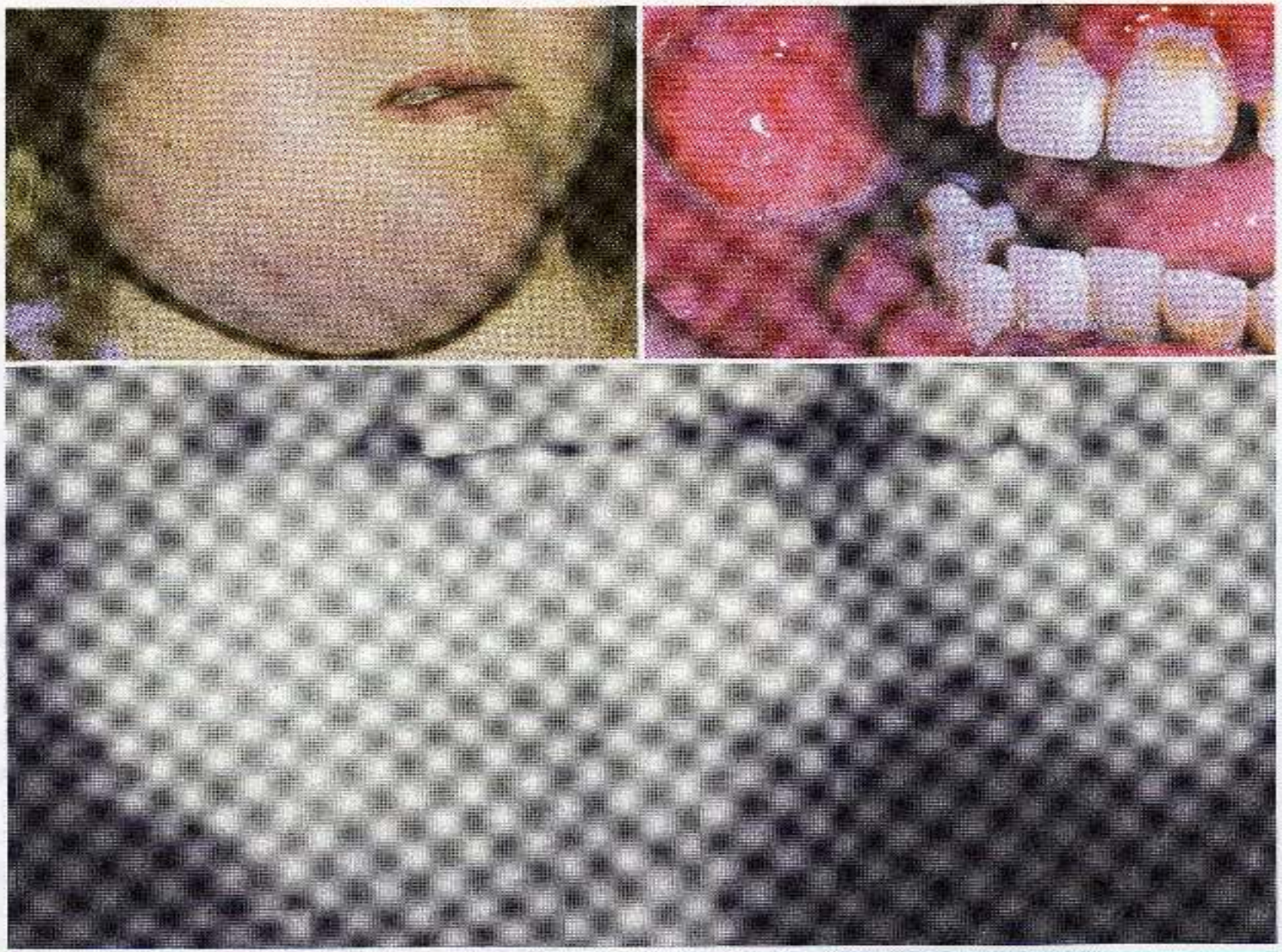

Figure 14-74 • **Osteosarcoma. A,** This massive tumor had been present for many months before the patient sought treatment. **B,** Intraoral photograph of the tumor mass. **C,** The panoramic radiograph shows a "sunburst" pattern of trabeculation within the tumor.

A

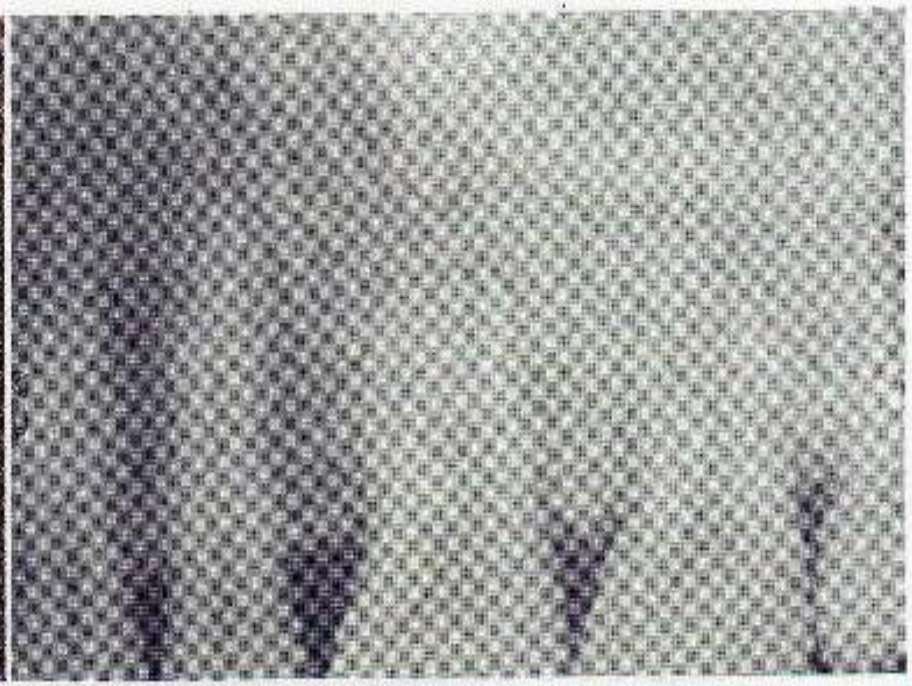

B

Osteosarcoma. A, This patient shows a firm, painful swelling of the left maxilla of recent onset. **B,** The periapical radiograph shows a dense sclerotic change in the bone pattern. (Courtesy of Dr. Len Morrow.)

OSTEOSARCOMA SURROUNDING THE ROOTS OF FIRST MOLAR TOOTH. NOTE WIDENED PERIODONTAL LIGAMENT

Radiographically:.

- The border is mostly ill defined, making it difficult to determine the extent of the tumor.
- Occasionally, there is resorption of the roots of the teeth involved by the tumor.
- The classical sunburst, or sunray appearance is due to the osteophytic bone production on the surface of the lesion noted in about 25% of jaw osteosarcoma, mostly seen on an occlusal projection.

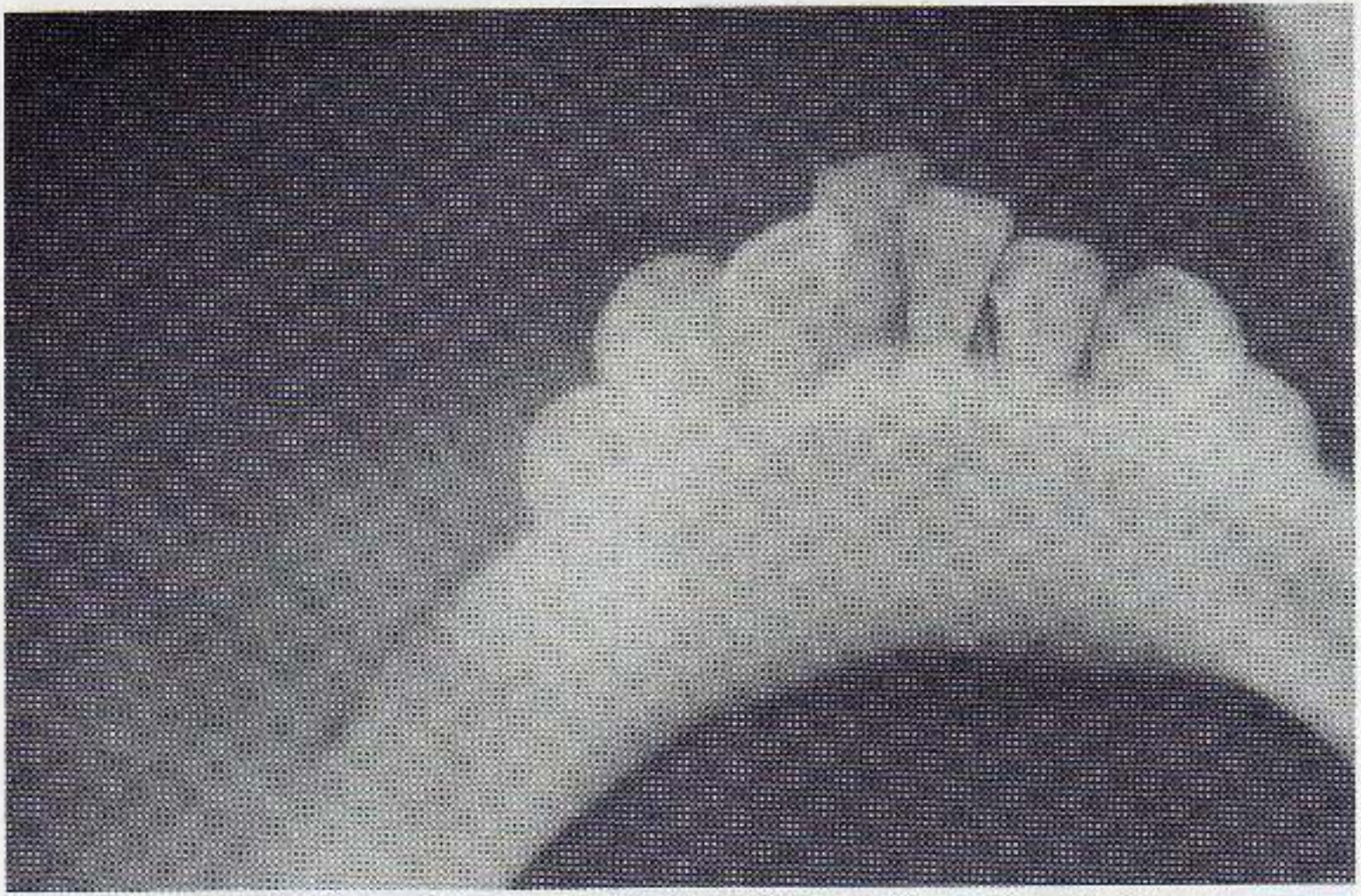

Figure 14-75 • Osteosarcoma. Occlusal radiograph demonstrating prominent exophytic tumor bone production on the buccal surface of the mandible, resulting in the "sunburst" pattern. (Courtesy of Dr. Lewis Gilbert.)

OSTEOSARCOMA OF THE MANDIBLE SHOWING A SUNBURST PATTERN OF TUMOR BONE RADIATING FROM THE ALVEOLAR RIDGE.

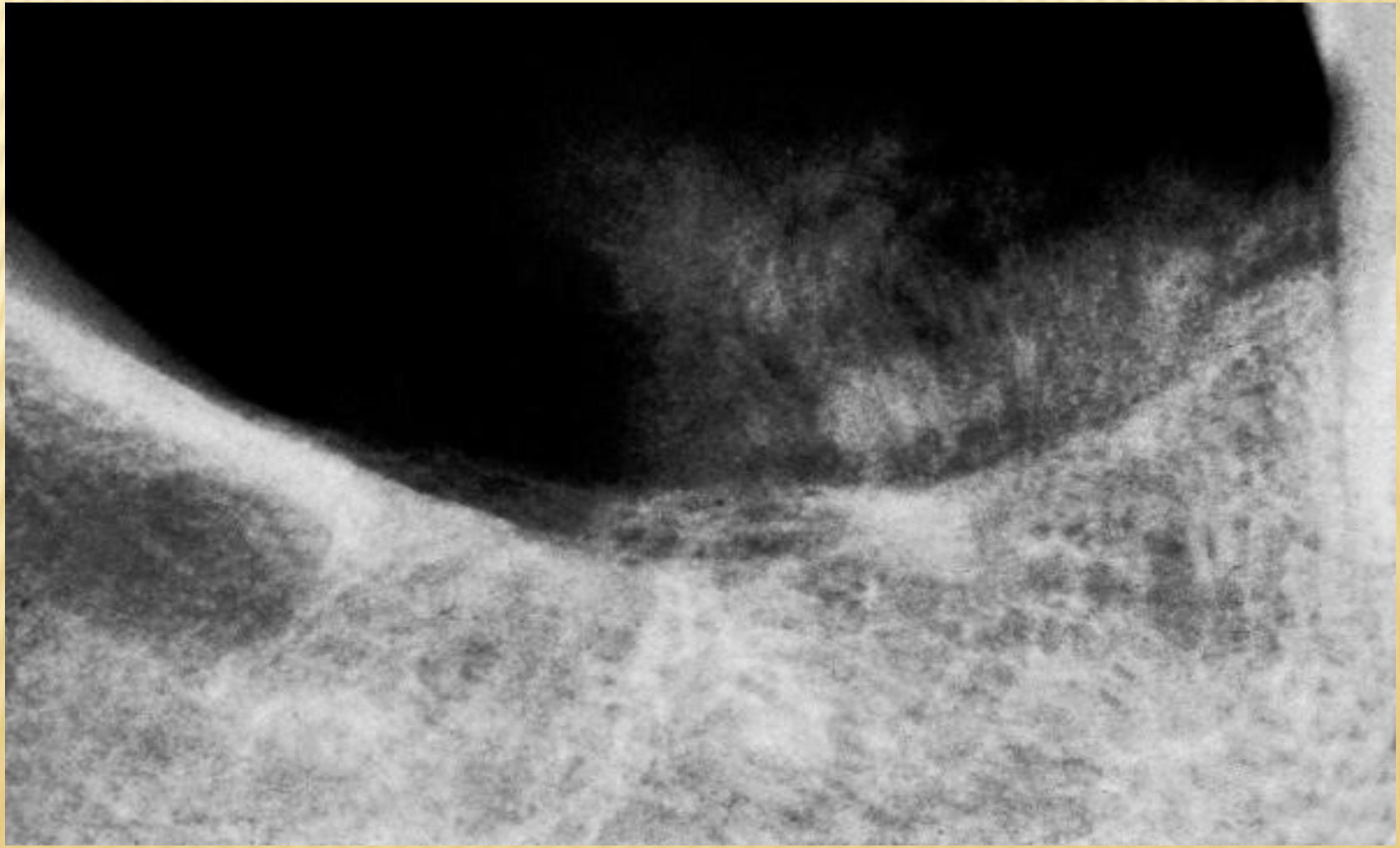

Microscopic Findings

The key feature for the diagnosis is the detection, somewhere in the tumor, of osteoid and for bone (calcified osteoid) produced directly by the tumor cells, without interposition of cartilage.

Osteoid is recognized by its eosinophilic-staining quality, its glassy appearance, irregular contours, and the fact that it is surrounded by a rim of osteoblasts

Microscopic Findings

Depending on the relative amounts of osteoid, cartilage, or collagen fibers produced by the tumor, many pathologists subclassify osteosarcomas into the following types:

- osteoblastic.
- chondroblastic.
- fibroblastic.

D, SURGICAL SPECIMEN OF THE HIGH-GRADE TUMOR (CHONDROBLASTIC OSTEOSARCOMA).

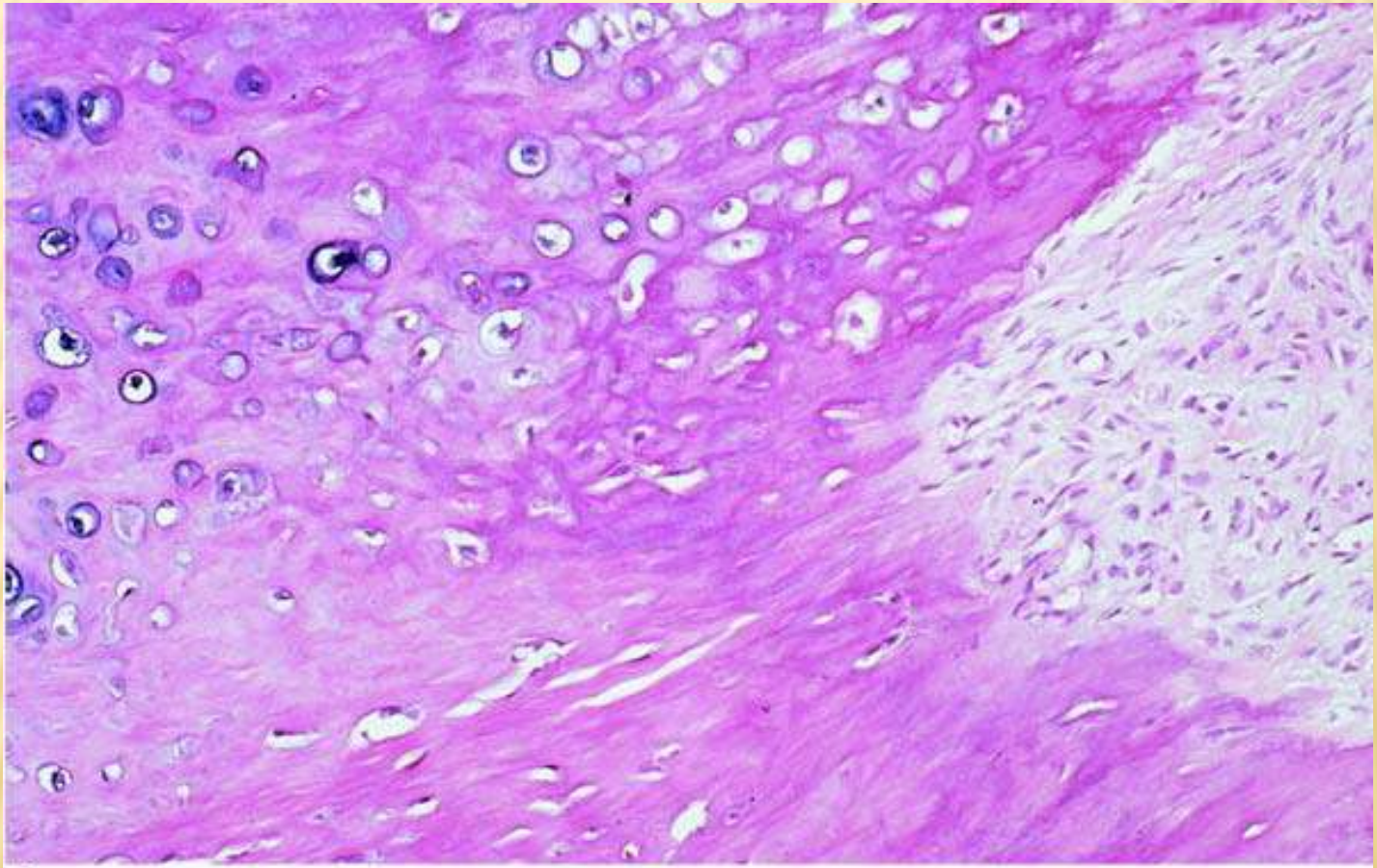

D

CHONDROBLASTIC OSTEOSARCOMA. NOTE CARTILAGE AND BONE AT LOWER LEFT.

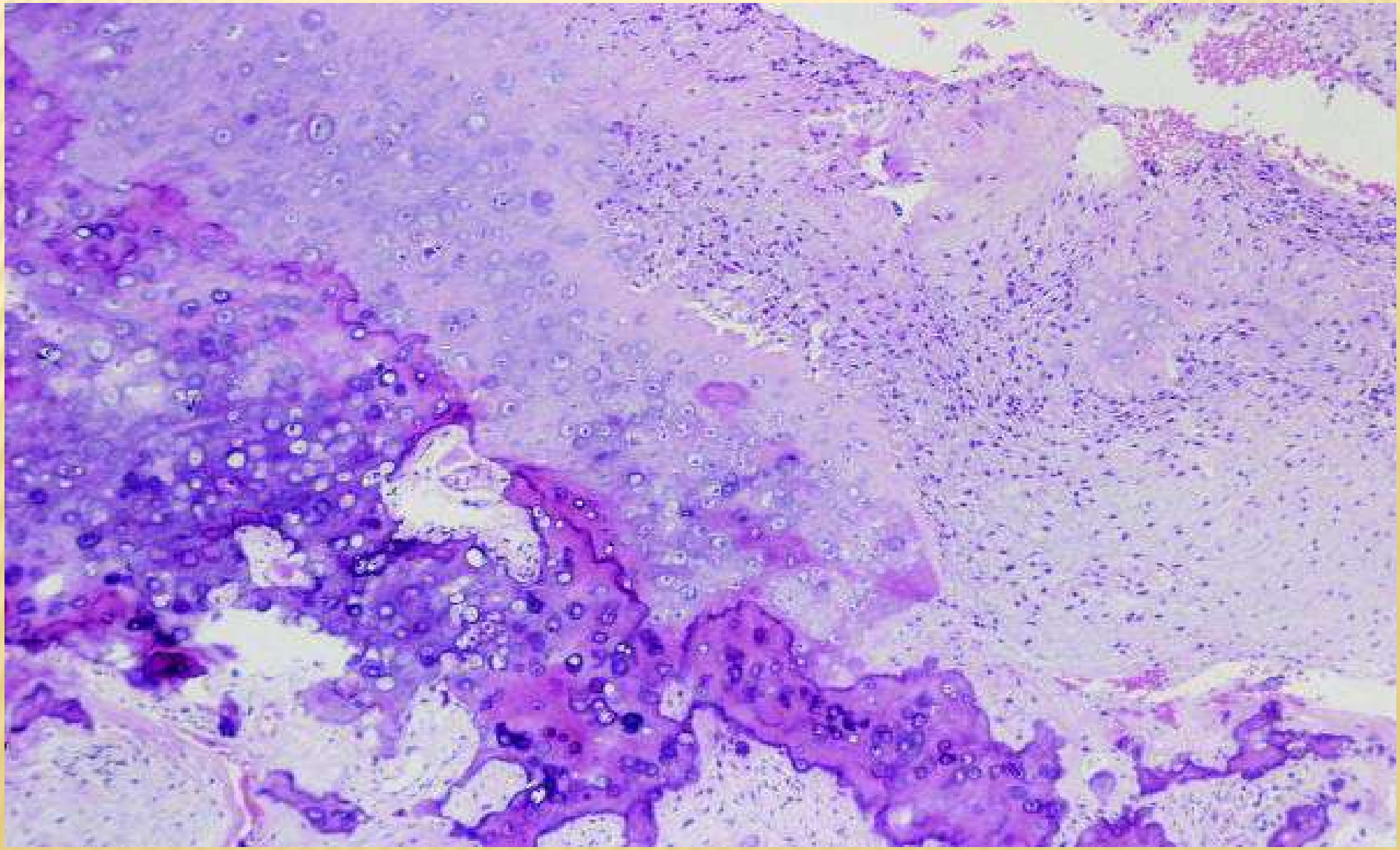

FIBROBLASTIC OSTEOSARCOMA COMPOSED OF SPINDLED TUMOR CELLS AND SMALL ISLANDS OF TUMOR BONE.

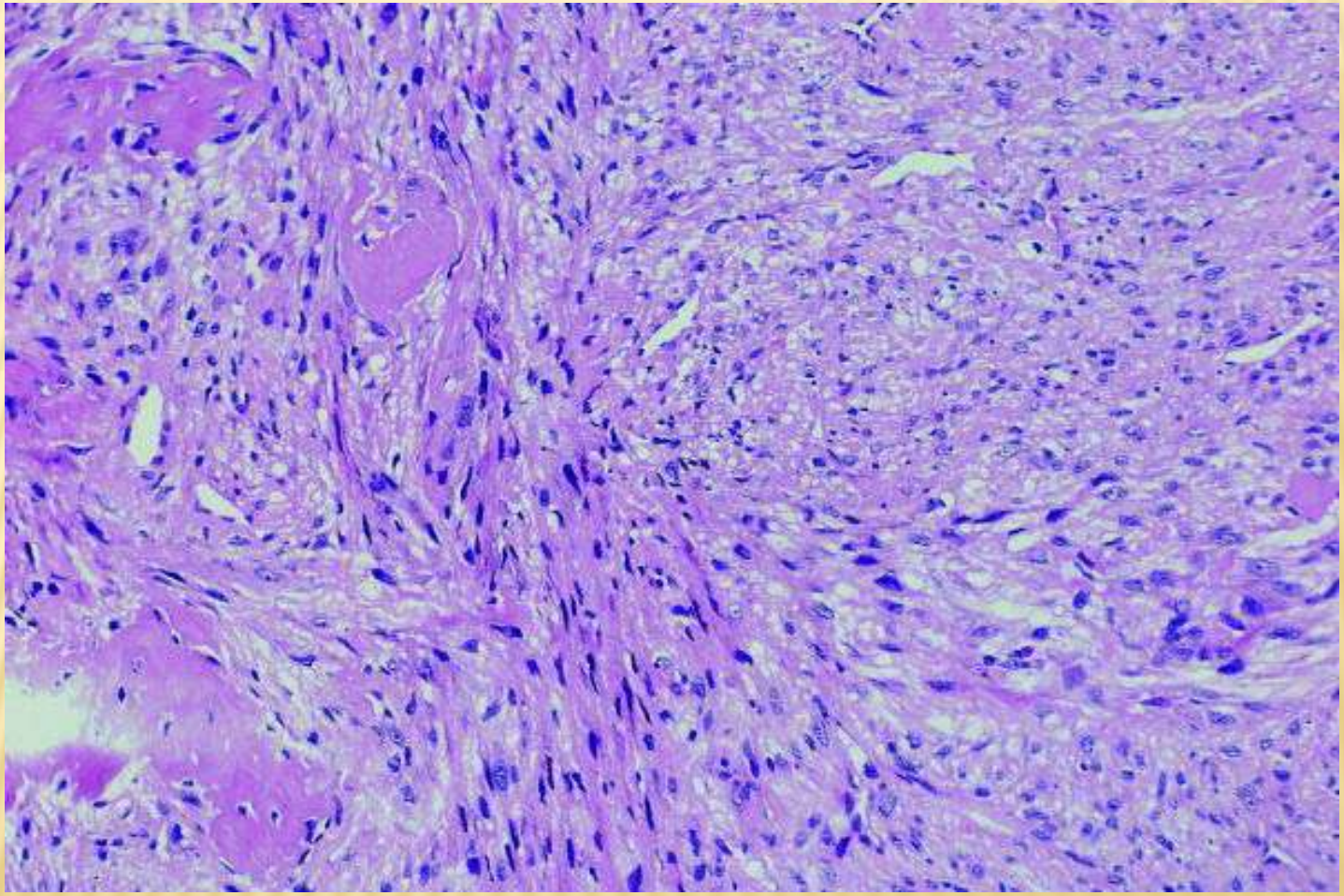

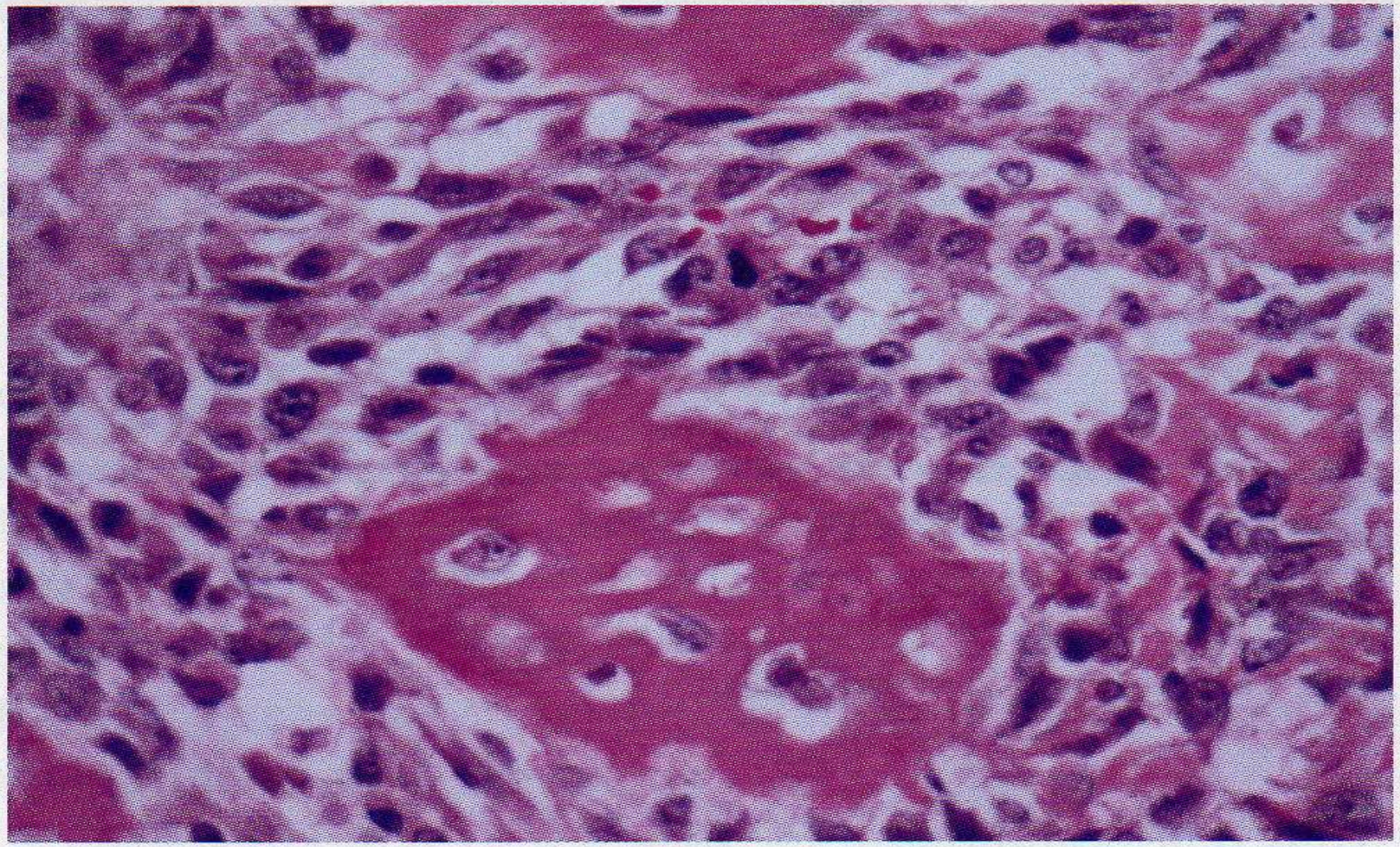

Figure 14-77 • Osteosarcoma. Anaplastic tumor cells forming cellular disorganized bone.

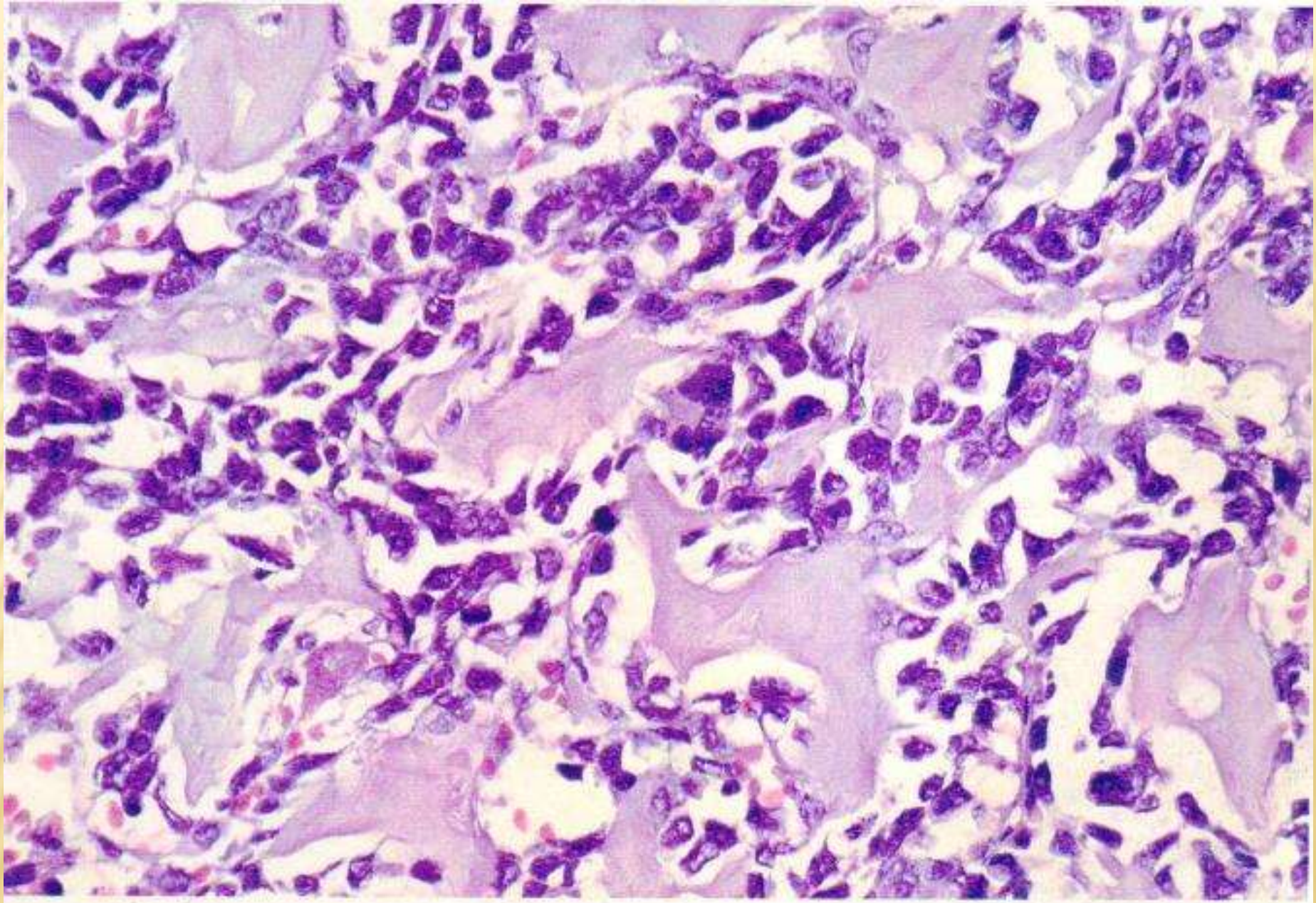

Fig. 18. Osteosarcoma
Tumour osteoid

A AND B, OSTEOSARCOMA COMPOSED OF ATYPICAL CELLS IN ASSOCIATION WITH TUMOR BONE.

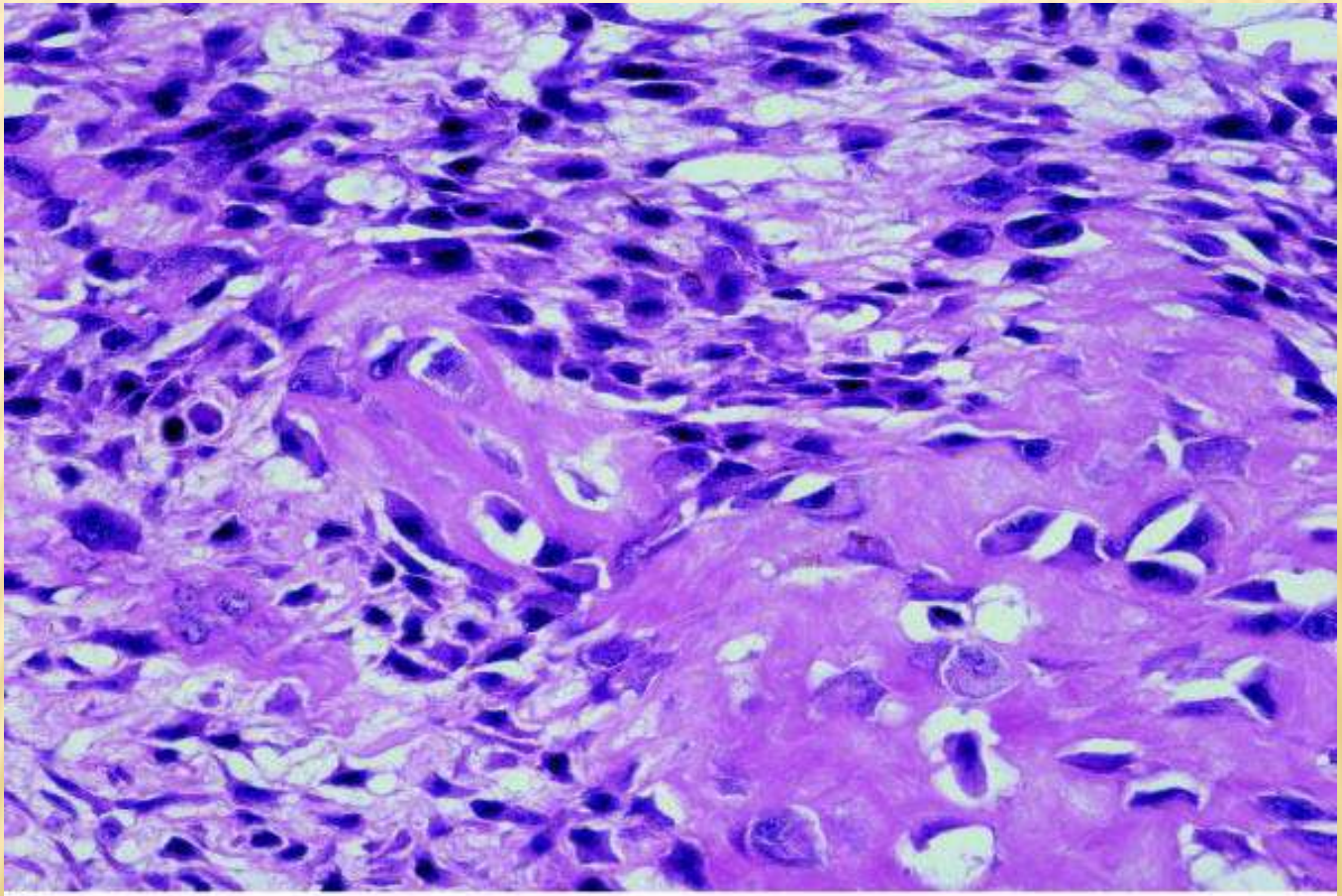

B

CARTILAGE FORMING TUMORS

- Chondromas are benign tumors composed of mature hyaline cartilage. It is one of the more common bone tumors and are located most often in the short tubular bones of the hand and feet.

- Chondroma appears as a circumscribed mass of mature hyaline cartilage, with well formed lacunae containing small chondrocytes with pale cytoplasm and small round nuclei.

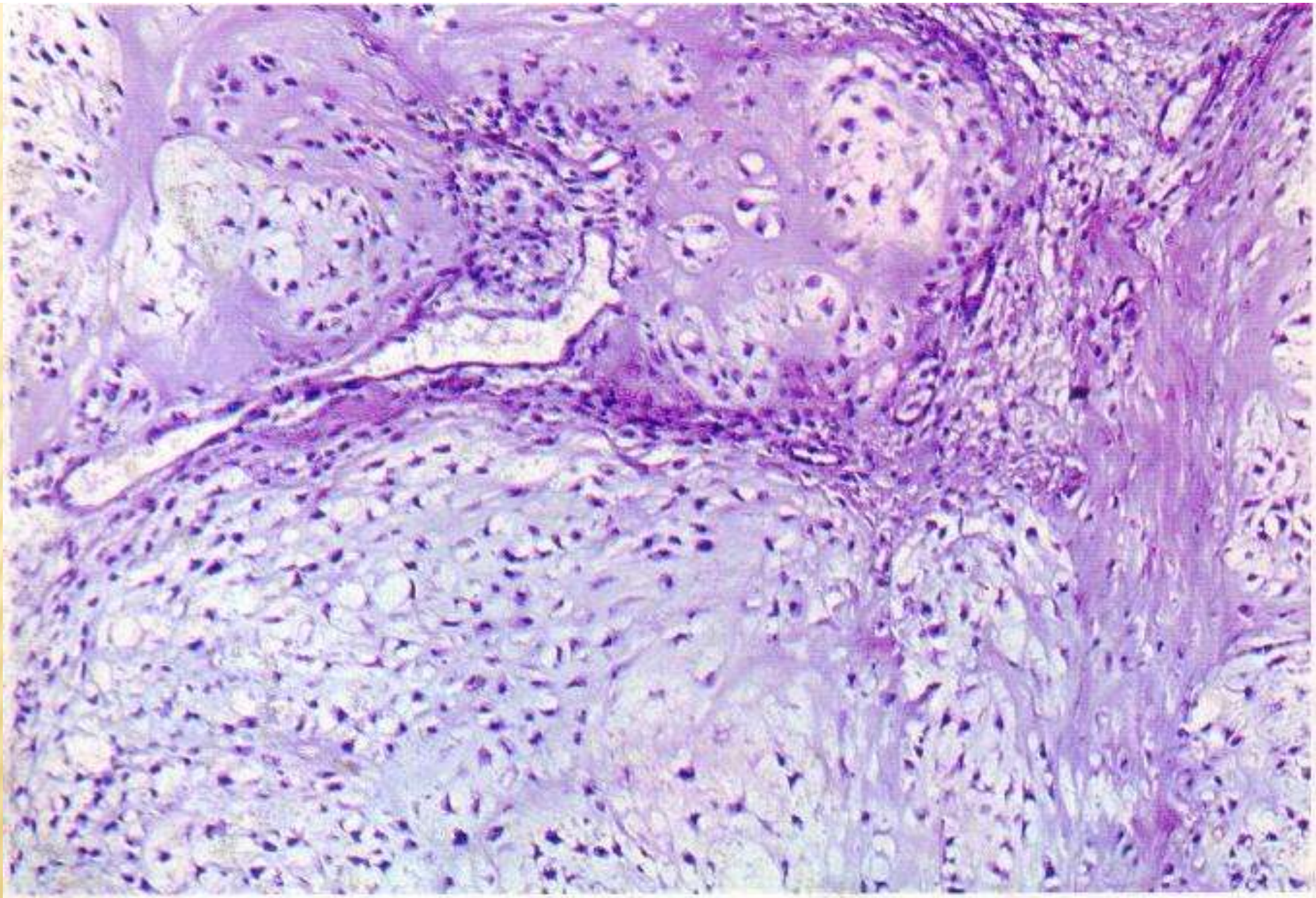

Fig. 32. Chondroma
Same case as Fig. 30

CHONDROSARCOMA

- A painless mass is the most common presenting sign. This may be associated with separation or loosening of teeth. In contrast to osteosarcoma, pain is an unusual complaint

HISTOPATHOLOGY

- Chondrosarcoma may be divided into 3 grades of malignancy, which correlates well with the rate of tumor growth and prognosis, e.g.
- **grade I**, closely resemble chondroma, which is composed of chondroid matrix and chondroblast, that show only subtle variation from the appearance of normal cartilage.
- The tumor should be considered malignant when large-plump chondroblasts and binucleated chondrocytes are present.

- Grade II, present with greater number of cells with moderately sized nuclei and increased cellularity.
- Grade III is highly cellular, with spindle cells proliferation. Mitoses may be prominent.

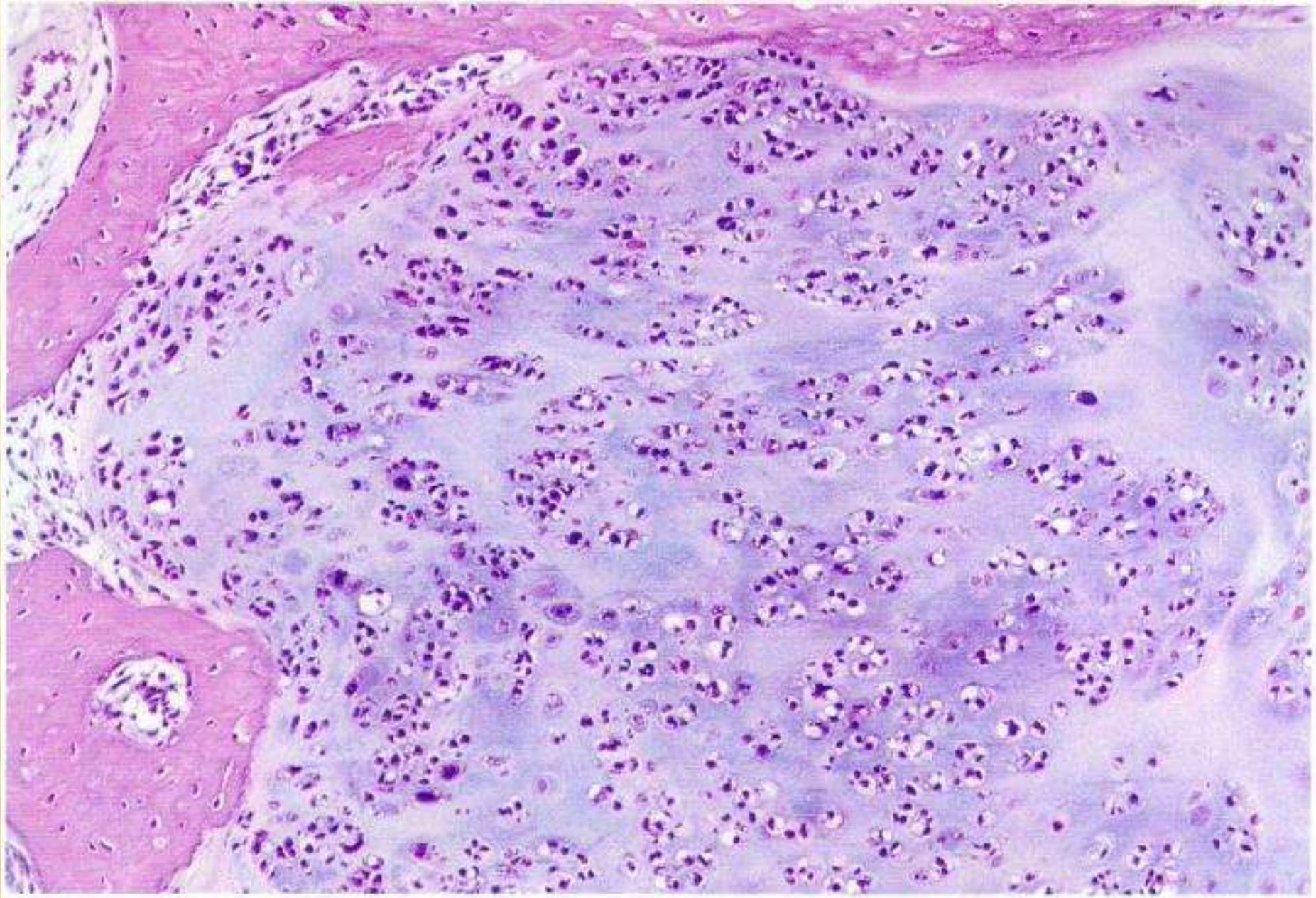

Fig. 49. Chondrosarcoma
Well differentiated tumour

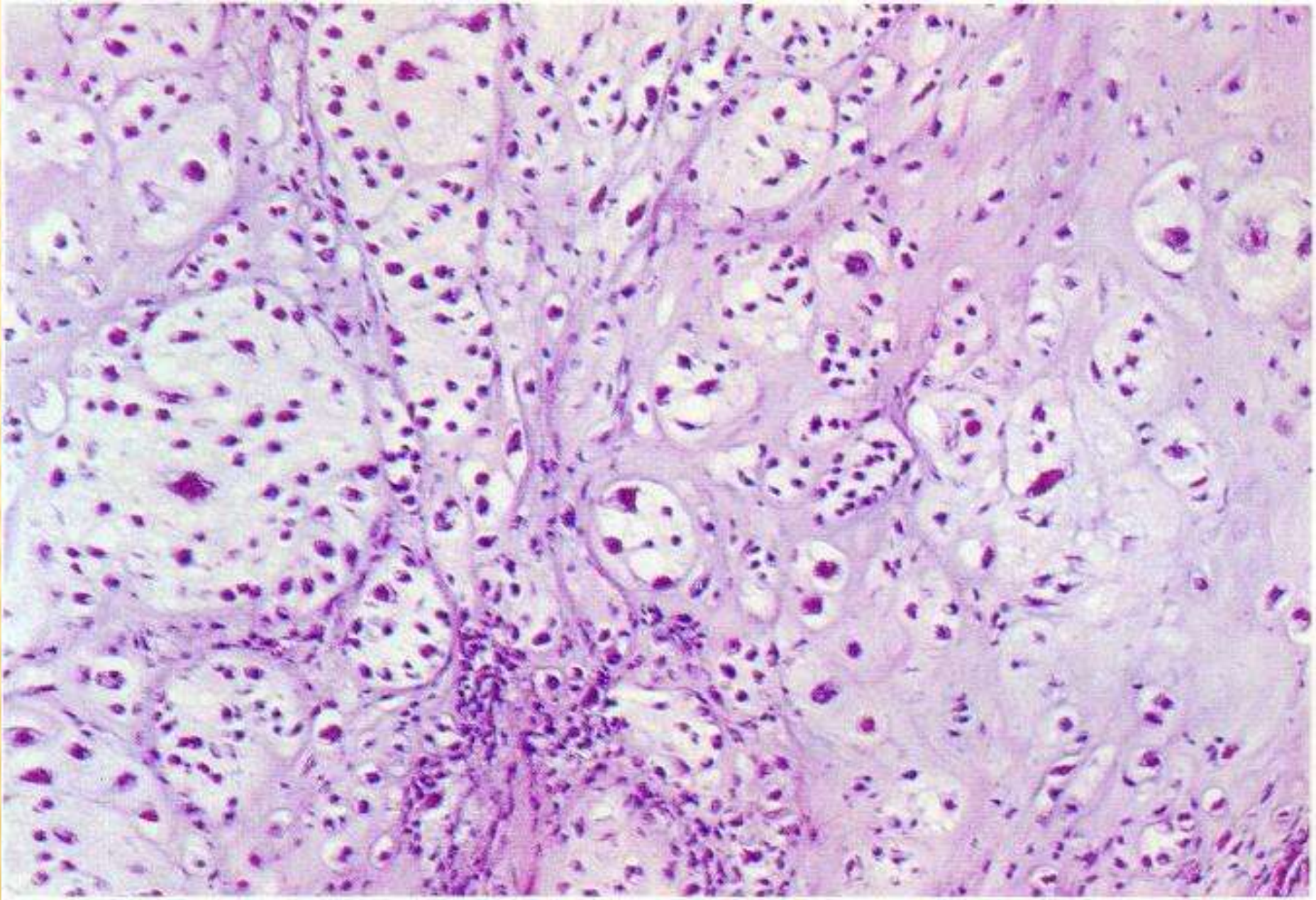

Fig. 53. Chondrosarcoma

Same case as Fig. 52. Pleomorphic cartilage

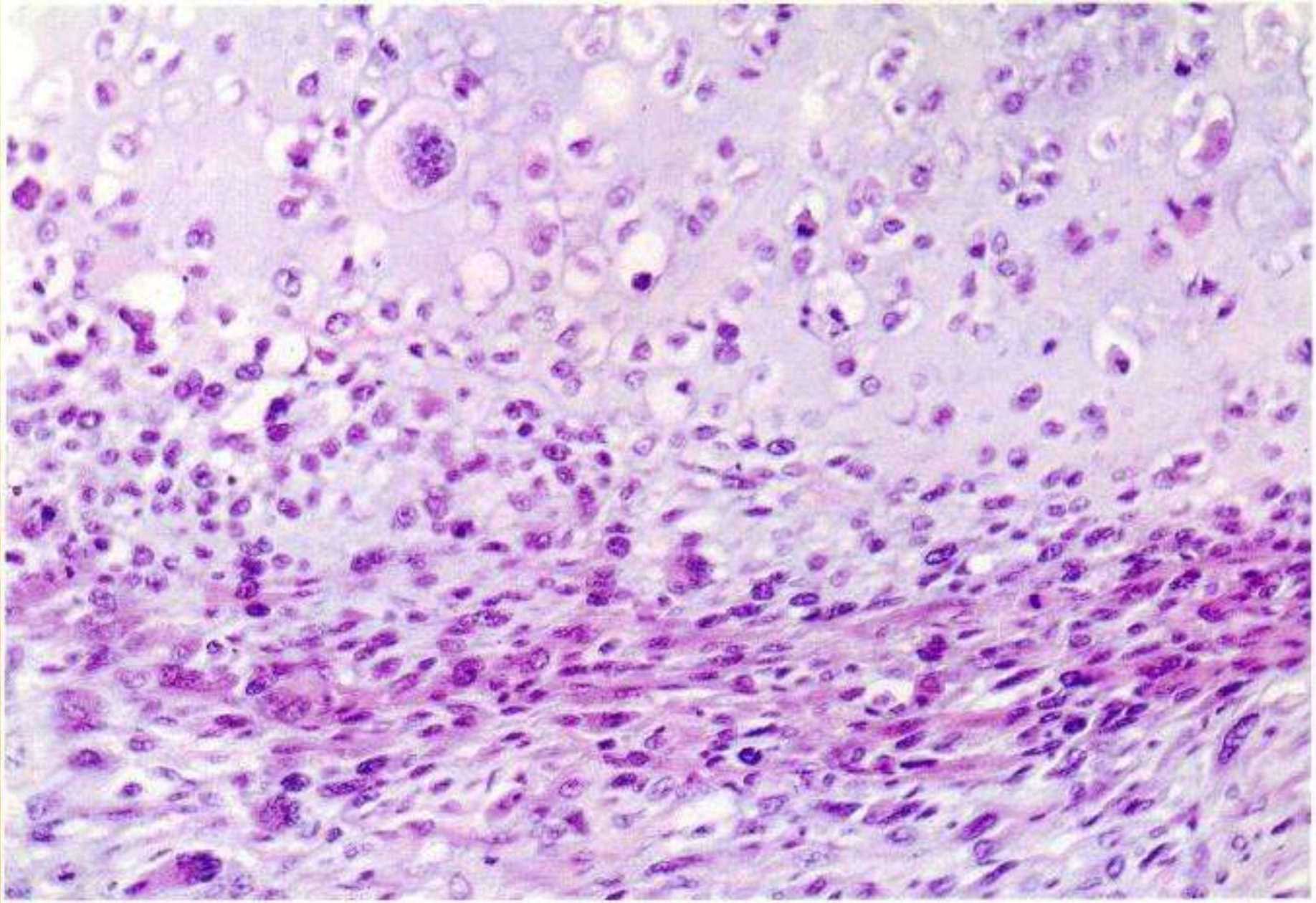

Fig. 55. Chondrosarcoma
Spindle-celled pattern

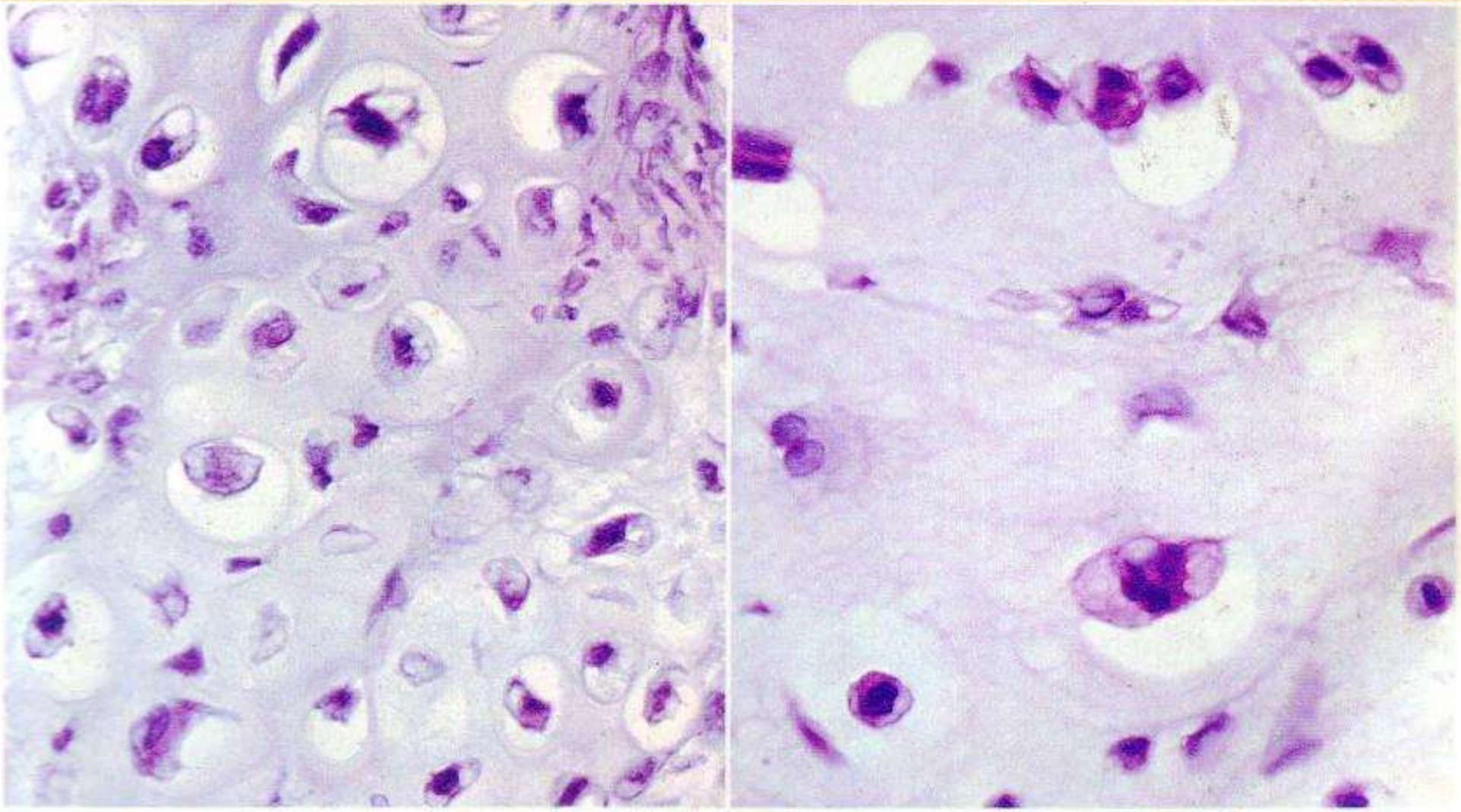

Fig. 54. Chondrosarcoma
Same case as Fig. 52

Malignant Lymphoma

Burkitt's Lymphomals a malignancy of B-lymphocyte origin that represents an undifferentiated lymphoma and it seems to have a predilection to jaws.

The classic starry sky pattern associated with the lesion is caused by the presence of histiocytes within the tumor tissue, which appear less intensely deeply stained malignant lymphocytes.

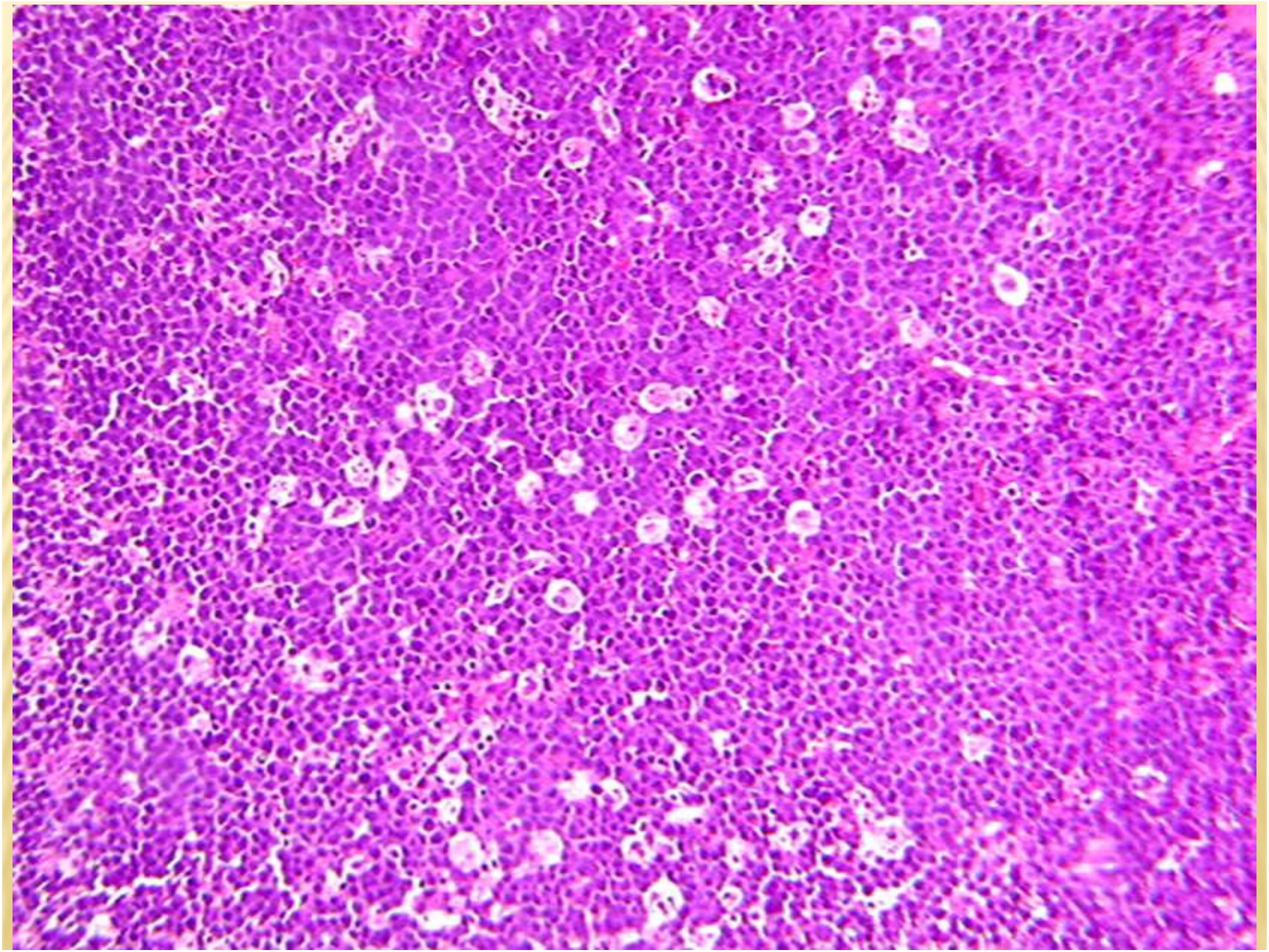

BURKITT'S LYMPHOMA EXHIBITING STARRY SKY EFFECT. PALE CELLS ARE TINGIBLE BODY MACROPHAGES.

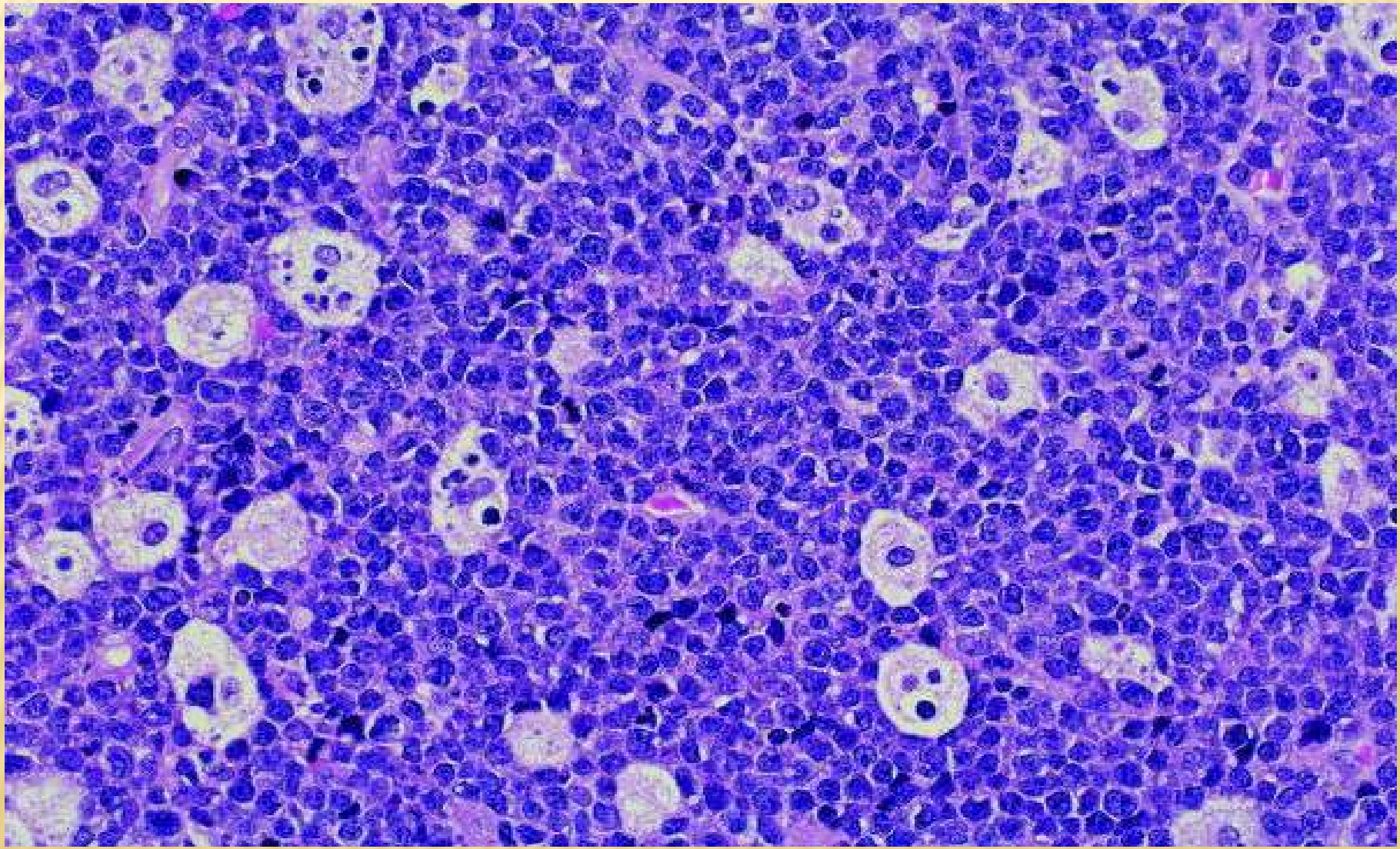

Thank you